



Case Report

Drug Induced Gingival Overgrowth In Elderly Stroke : A Case Report

¹Rizaldy Taslim Pinzon, ²Hanshel Everad Nathanael

^{1,2} Duta Wacana Christian University School of Medicine, Yogyakarta, Indonesia

^{1,2} Neurology Department, Bethesda Hospital, Yogyakarta, Indonesia

E-mail Corresponding: drpinzon17@gmail.com

Article History:

Submitted Oct 23, 2023

Review Dec 14, 2023

Accepted Sep 10, 2024

Keyword:

Gingival

hypertrophy;

Amlodipin

DIGO

Adverse event



© 2024 Jambi Medical Journal

Published by Faculty of Medicine and Health Science Universitas Jambi.

This is an open access article under the CC BY-NC-SA license

<https://creativecommons.org/licenses/by-nc-sa/4.0/>

ABSTRACT

Background: Adverse effects such as drug-induced gingival overgrowth have been documented with specific medications, including amlodipine, in individuals prone to such reactions. The precise mechanism behind gingival hypertrophy is not fully understood and may be associated with multiple factors. This condition is linked to challenges in speech and chewing, as well as issues related to oral hygiene and aesthetic concerns.

Case Presentation: A 64-year-old male with post stroke and hypertension who experienced gingival enlargement after utilizing amlodipine for a duration of three years. The initial phase of management involved maintaining oral hygiene and substituting the identified medication.

Conclusion: A case of Drug-Induced Gingival Overgrowth associated with amlodipine on post stroke patient with hypertension that causing difficulties in mastication and diffuse gingival enlargement. After the amlodipine was substituted with candesartan and oral hygiene was performed, leading to significant alleviation of the symptoms.

INTRODUCTION

Gingival overgrowth triggered by drugs can manifest as a side effect in individuals prone to it.¹ Earlier studies have indicated significant, disfiguring enlargement of the gingiva, particularly in the anterior region, resulting in challenges related to both mastication and speech.^{1,2}

The cause of drug-induced gingival overgrowth is not well comprehended. Within the category of antihypertensive medications, particularly calcium channel blockers, nifedipine has been frequently identified as a primary contributor to drug-induced gingival hyperplasia. Amlodipine, categorized as a second-generation dihydropyridine calcium

channel blocker, exhibits an extended duration of action and fewer adverse effects compared to nifedipine.³ Instances of amlodipine-induced gum hyperplasia are scarce, as indicated by a limited number of case reports.^{1,2,3} This case report details a situation involving amlodipine-induced gingival enlargement, with a discussion on its management. Successful measures, including substituting the medication, employing appropriate non-surgical interventions, and maintaining excellent plaque control, resulted in the regression and prevention of the recurrence of drug-induced gingival overgrowth.

CASE PRESENTATION

A 64-year-old post stroke male with stable condition and controlled risk factors presented to the neurological clinic. During a routine examination, he reported experiencing swollen gums for the past eight months, with continuous and gradual progression. The patient had pain in his teeth and gums and had a foul-smelling watery discharge from his gums. This condition making it challenging for him to chew certain foods. The certain food intake caused mild bleeding. The patient regularly took low-dose aspirin (80 mg), amlodipine (10 mg), atorvastatin (20 mg), and

vitamin B12 (50 mg). The suspicion arose that the low-dose aspirin might be the cause of the bleeding. Despite temporarily discontinuing aspirin for two weeks, the issues persisted. Comprehensive laboratory tests for bleeding, including haemostatic parameters, platelet count, bleeding time, fibrinogen, and PTT, showed no abnormalities.

We referred the patients to the dental clinic. The intraoral inspection indicated diffuse gingival enlargement affecting marginal, attached, and interdental gingiva on the buccal and lingual/palatal sides of the maxillary and mandibular anterior teeth, with mandibular gingiva exhibiting more severe changes. The patient maintained a moderate level of oral hygiene. Upon examination, the enlarged gingiva appeared solid, fibrous, and non-tender. The dental report suggested a diagnosis of Drug-Induced Gingival Overgrowth (DIGO).

Upon reviewing previous studies on DIGO, it was found that the patient had been consistently taking 10 mg amlodipine from the same brand for three years for hypertension and post stroke. He did not report having similar symptoms previously, and there were no reported changes in medication history, and no family history of similar symptoms was noted.

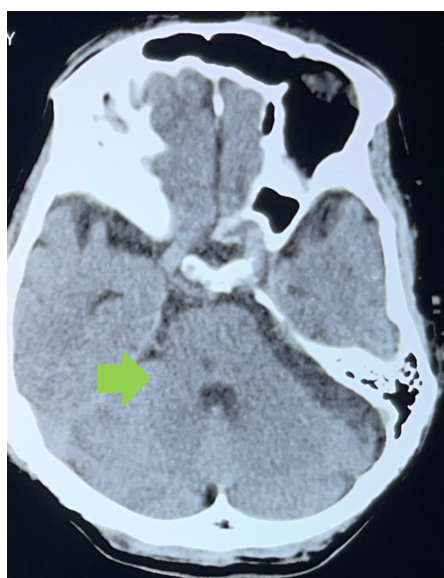


Figure 1. The CT Scan showed old lacunar infarction in the brain stem

After a second consultation with the dental department, a provisional diagnosis of amlodipine-induced gum enlargement superimposed with inflammation was established on clinical evaluation. The patient underwent procedures for mechanical and chemical removal of plaque, along with guidance on maintaining oral hygiene. He was

then referred to our department to change the medication. Subsequently, a change in medication was recommended, and the patient started taking candesartan (16 mg). After 6 weeks, there were no significant complaints related to mastication and bleeding tendency, and the swelling was improved.

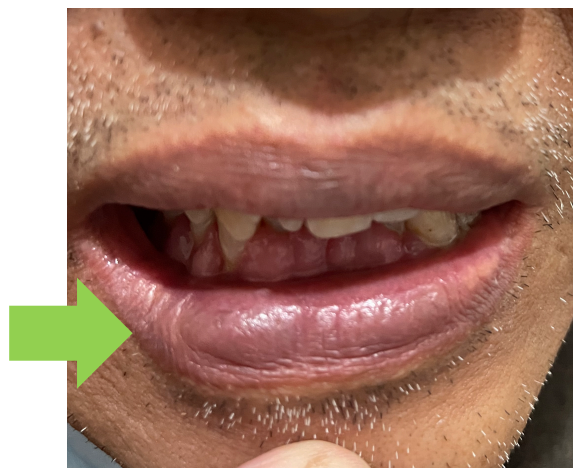

Figure 2. Gingival hypertrophy in patient with long time amlodipine consumption

DISCUSSION

We report a case of Amlodipine induced gingival hypertrophy in post stroke patients with hypertension. Previous reports mentioned that drug-induced gingival overgrowth (DIGO) is a frequent adverse event that is generally related with immunosuppressants, anticonvulsants, and calcium channel blockers like cyclosporine, phenytoin, and nifedipine.^{4,5} Our case underscores the significance of Amlodipine, the most prescribed anti-hypertension medication, in causing this adverse event. This highlights the need for increased awareness among physicians regarding Amlodipine's potential to induce DIGO, especially in post-stroke patients with hypertension.

Among the calcium channel blocker anti-hypertension. Amlodipine was not reported as many as nifedipine that related with DIGO.^{6,7} Previous review showed that there is rising pattern in the quantity of cases indicating that Cyclosporine (44.89%) is the

frequently utilized used drug most closely associated with DIGO, followed by phenytoin (18.22%), nifedipine (17.93%), and amlodipine (6.81%).^{8,9}

The precise mechanism of Drug-Induced Gingival Overgrowth is yet to be determined, but there have been several proposed hypotheses.^{10,11} Previous reports have outlined two main pathways: one involving inflammation and the other non-inflammatory. Amlodipine's pharmacotherapeutic effect aim reducing the blood pressure, triggers the release of renin and angiotensin-converting enzyme. This process results in the overproduction of androgens and adrenocorticotrophic hormone (ACTH), contributing to kidney hypertrophy. This excess androgens are believed to impact the gingival tissue, stimulating fibroblast proliferation and collagen production, ultimately leading to gingival tissue overgrowth.¹² There is a potential genetic predisposition to Drug-Induced Gingival Overgrowth (DIGO). This hypothesis based on

the fact that among individuals using the same medication with the same frequency, only subsets develop DIGO. Furthermore, the severity of gingival overgrowth varies among individuals. Although various genotypes have been suggested, but the specific genetic linkage remains undetermined.^{13,14}

In patients with post stroke and hypertension, amlodipine may be one of the commonest medications. It is recommended that oral health should be included into the care plan for this patient group.^{15,16} Managing Drug-Induced Gingival Overgrowth (DIGO) may involve providing guidance on oral hygiene, professional scaling and root planning, considering surgical intervention, and, if necessary, discontinuation or replacement the suspected medication^{17,18}.

The initial approach in managing DIGO involves discontinuing the suspected medication and substituting it with an

alternative. It is crucial to maintain good oral hygiene practices, including plaque cleaning by dental professionals. In persistent cases, the consideration of gingivectomy, with or without flap surgery, may be warranted.^{19,20} In our patient, we substitute the Amlodipine with Candesartan accompanied by dental consultation, plaque cleaning, and improvements in oral hygiene. The result was remarkable for the patients.

CONCLUSION

We reported a case of Drug-Induced Gingival Overgrowth linked to amlodipine, resulting in challenges with mastication, accumulation of plaque, and undesirable aesthetic concerns. The individuals received oral hygiene treatment and amlodipine was substituted with candesartan, leading to a significant alleviation of the symptoms.

REFERENCES

1. Banthia R, Jain P, Banthia P, Belludi S, Jain AK. Amlodipine- induced gingival overgrowth: a case report. *J Mich Dent Assoc.* 2012 Sep;94(9):48–51.
2. Reddy SC, Midha N, Chhabra V, Kumar D, Bohra GK. Amlodipine Induced Gum Hypertrophy: A Rare Case Report. *Vol. 17, Current drug safety. United Arab Emirates; 2022. p. 281–3.*
3. Zhang R, Wu J, Zhu J, Wang X, Song J. Bibliometric analysis of research trends and characteristics of drug-induced gingival overgrowth. *Front public Heal.* 2022;10:979861.
4. Bajkovec L, Mrzljak A, Likic R, Alajbeg I. Drug-induced gingival overgrowth in cardiovascular patients. *World J Cardiol.* 2021 Apr;13(4):68–75.
5. Quenel L, Keribin P, Giran G, Tessier M-H, Lesclous P. Amlodipine-induced gingival enlargement: A case report. *Vol. 121, Journal of stomatology, oral and maxillofacial surgery. France; 2020. p. 308–11.*
6. Fardal Ø, Lygre H. Management of periodontal disease in patients using calcium channel blockers - gingival overgrowth, prescribed medications, treatment responses and added treatment costs. *J Clin Periodontol.* 2015 Jul;42(7):640–6.
7. Damdoun M, Varma SR, Nambiar M, Venugopal A. Calcium Channel Blockers Induced Gingival Overgrowth: A Comprehensive Review from a Dental Perspective. *J Int Soc Prev Community Dent.* 2022;12(3):309–22.
8. Bhandari S, Siwakoti S, Shrestha S, Gautam K, Bhandari S. Drug-Induced Gum Overgrowth With Low-Dose Amlodipine: A Case Report. *Vol. 14, Cureus. United States; 2022. p. e25220.*
9. Li, R., Fan, W., Li, D., & Liu, X. 2022.. Correlation of common inflammatory cytokines with cognition impairment, anxiety, and depression in acute ischemic stroke patients. *Brazilian journal of medical and biological research = Revista brasileira de pesquisas medicas e biologicas*, 55, e11517. <https://doi.org/10.1590/1414-431X2021e11517>
10. Surawan, J., Sirithanawutichai, T., Areemit, S., Tiamkao, S., & Saensak, S. 2018. Prevalence and factors associated with memory disturbance and dementia after acute ischemic stroke. *Neurology international*, 10(3), 7761. <https://doi.org/10.4081/ni.2018.7761>
11. Weimar, C. 2012. Stroke: Initial stroke volume is an independent outcome predictor, *Nature Reviews Neurology*, 8(6), p. 305. Available at: <https://doi.org/10.1038/nrneurol.2012.91>.

12. Fekadu, G., Chelkeba, L. and Kebede, A. 2019. Risk factors, clinical presentations and predictors of stroke among adult patients admitted to stroke unit of Jimma university medical center, south west Ethiopia: Prospective observational study, *BMC Neurology*, 19, p. 187. Available at: <https://doi.org/10.1186/s12883-019-1412-5>.
13. Soliman, R. H., Oraby, M. I., Fathy, M., & Essam, A. M. 2018. Risk factors of acute ischemic stroke in patients presented to Beni-Suef University Hospital: prevalence and relation to stroke severity at presentation. *The Egyptian journal of neurology, psychiatry and neurosurgery*, 54(1), 8. <https://doi.org/10.1186/s41983-018-0012-4>
14. Lee, J. H., Lee, J. Y., Ahn, S. H., Jang, M. U., Oh, M. S., Kim, C. H., Yu, K. H., & Lee, B. C. 2015. Smoking is Not a Good Prognostic Factor following First-Ever Acute Ischemic Stroke. *Journal of stroke*, 17(2), 177–191. <https://doi.org/10.5853/jos.2015.17.2.177>
15. Kim, S.H., Lee, J.Y., Kim D.H., Ham J.H., Song Y.K., Lim E.J., et al et al. 2013. Factors related to the initial stroke severity of posterior circulation ischemic stroke , *Cerebrovascular Diseases*, 36, pp. 62–68. <https://doi.org/10.1159/000351512>.
16. Wojda M., Świstowska M., Wielgosz A., Mincewicz A., Wach D., Iwaniuk K. et al.. gingival overgrowth during hypertension therapy. a case report and literature review. *Quality in Sport* 2024;16:52604. <https://doi.org/10.12775/qs.2024.16.52604>
17. Aghanashini D.. Amlodipine induced gingival overgrowth and its nonsurgical management– a case report. *Journal of Medical Science and Clinical Research* 2019;7(3). <https://doi.org/10.18535/jmscr/v7i3.79>
18. Farook F., Nizam M., & Alshammari A.. An update on the mechanisms of phenytoin induced gingival overgrowth. *The Open Dentistry Journal* 2019;13(1):430-435. <https://doi.org/10.2174/1874210601913010430>
19. Kaomongkolgit R.. Amlodipine-induced gingival overgrowth in older patients: a report of four cases. 2023;18(1):36-38. <https://doi.org/10.12809/ajgg-2022-526-cr>
20. Gallo C., Bonvento G., Zagotto G., & Mucignat-Caretta C.. gingival overgrowth induced by anticonvulsant drugs: a cross-sectional study on epileptic patients. *Journal of Periodontal Research* 2020;56(2):363-369. <https://doi.org/10.1111/jre.12828>